

A&P Lab Quiz #9  
Cardiovascular System  
Respiratory System

# Anatomy of the heart

Anterior (front) view

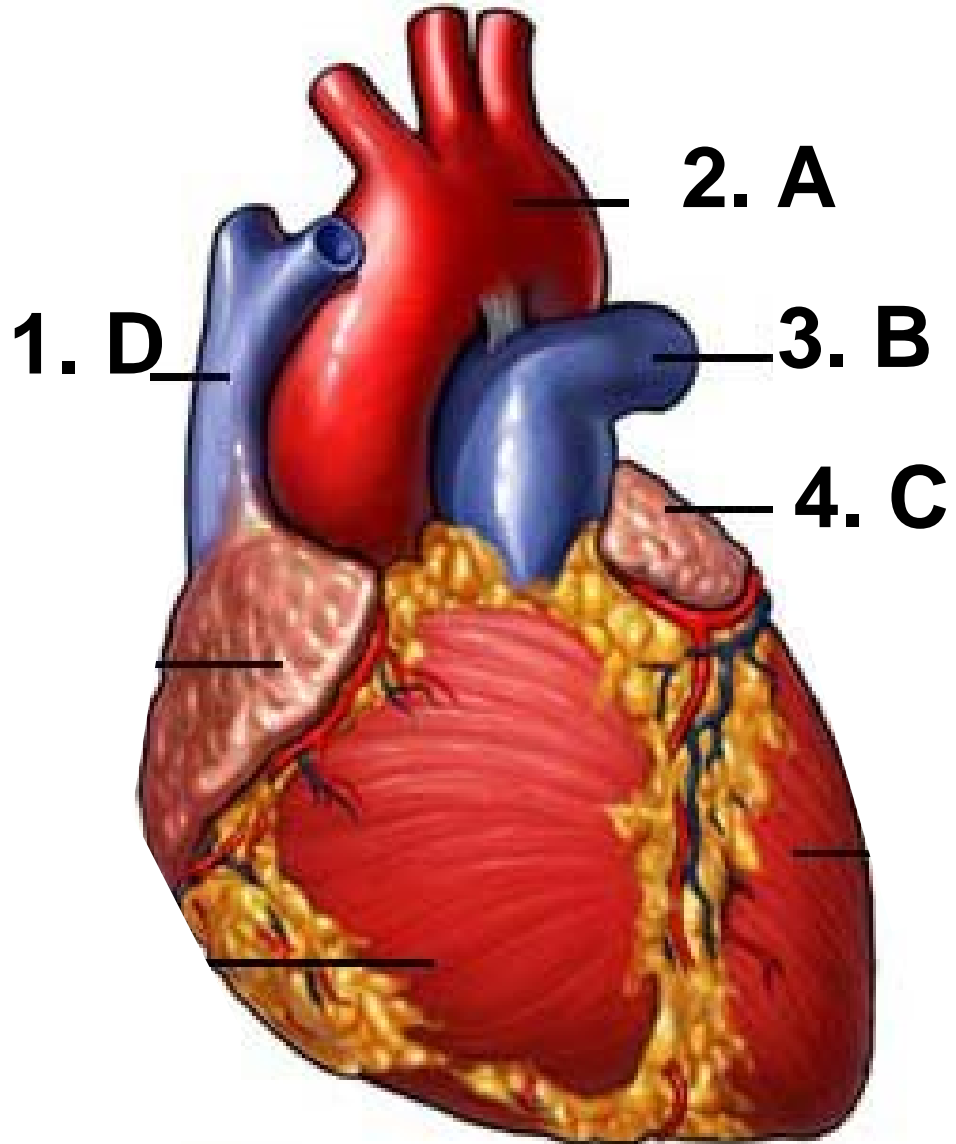
a. Aorta

b. Pulmonary trunk

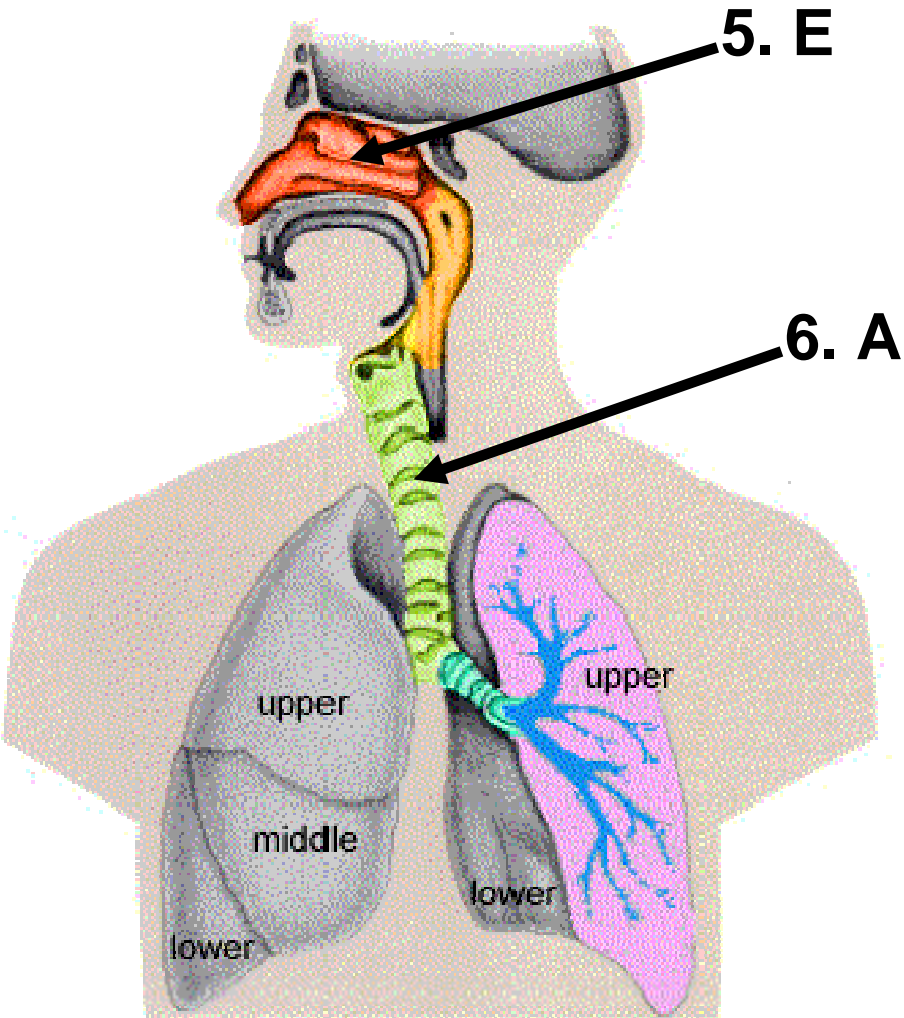
c. Atrium

d. Vena cava

e. apex



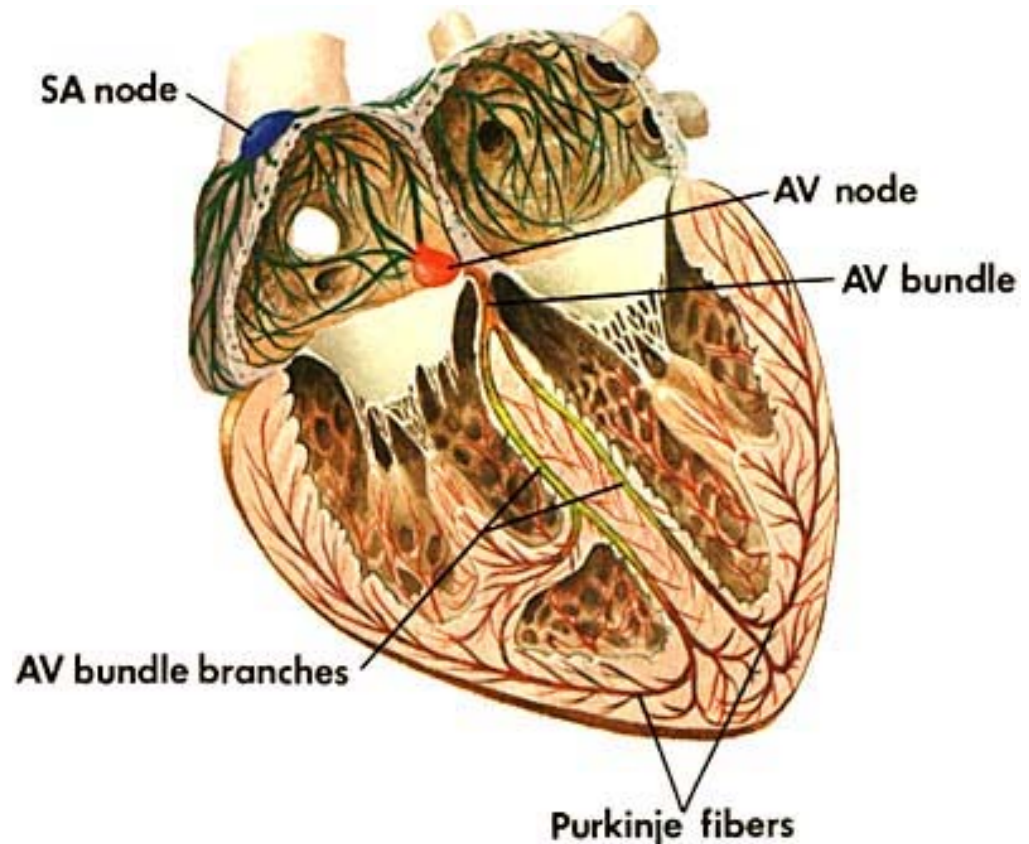
# NAME THIS STRUCTURE



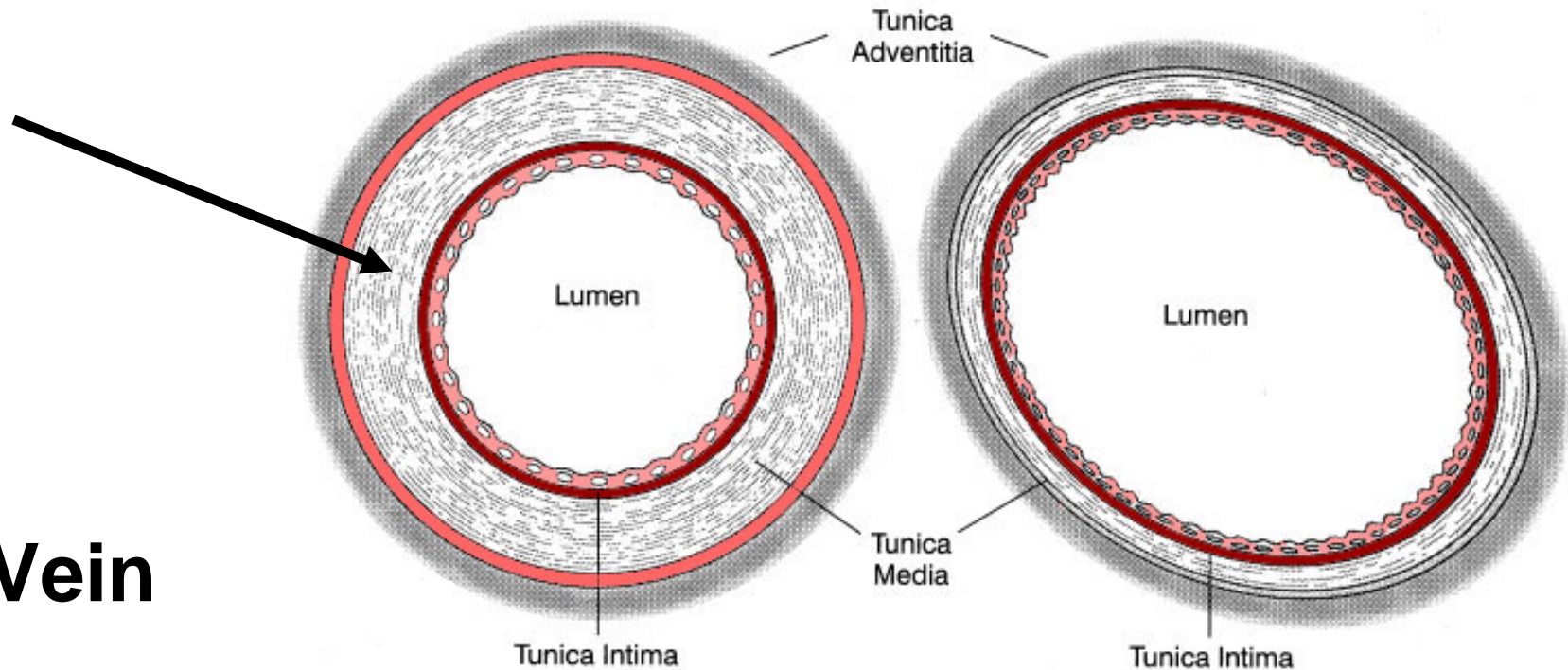
- a. Trachea
- b. Bronchiole
- c. Bronchus
- d. Pharynx
- e. Nasal cavity

# 7. Which neural tissue is the “pacemaker” of the heart?

- a. Purkinje fibers
- b. AV Bundle
- c. AV Branches
- d. AV node
- e. SA node



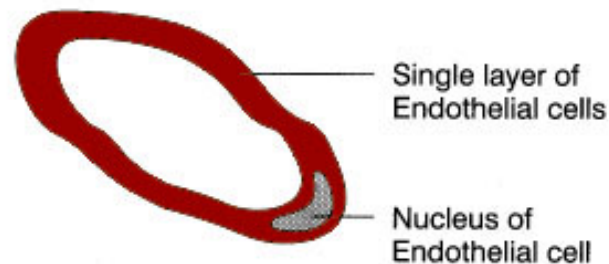
# 8. What type of blood vessel?

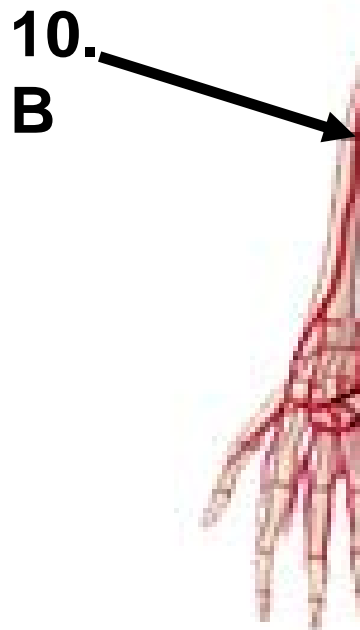

a. Vein

b. Artery

c. Capillary

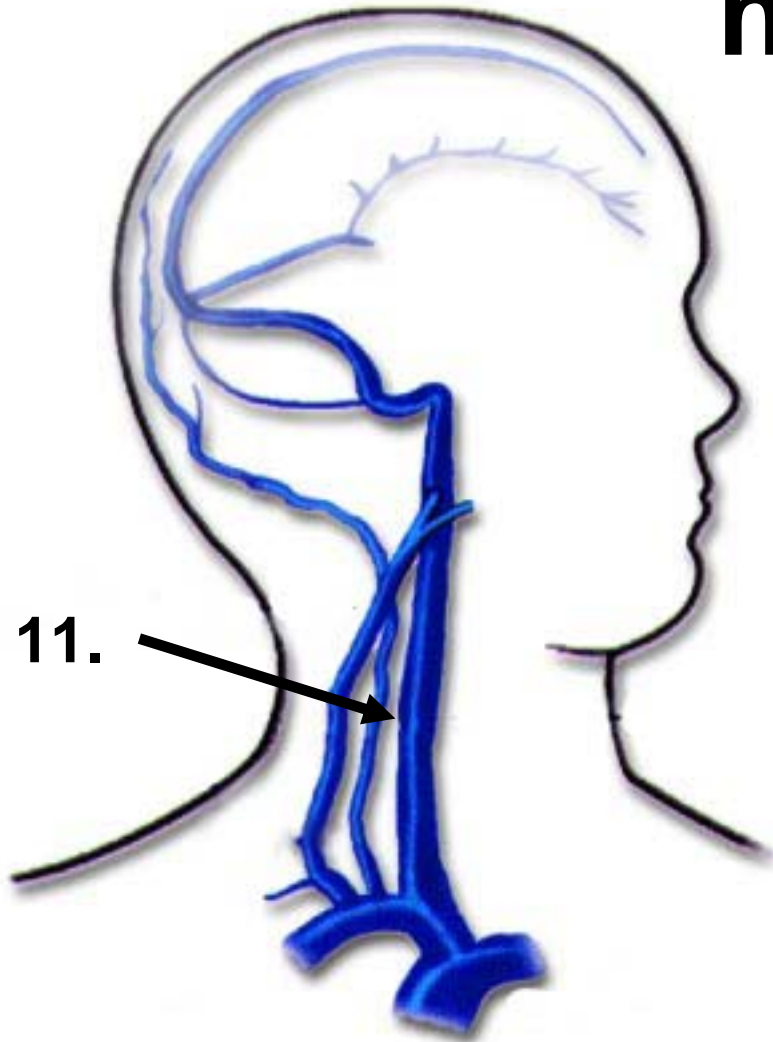




**Name this major  
ARTERY of the arm**

- a. Ulnar**
- b. Radial**
- c. Brachial**
- d. Axillary**
- e. Subclavian**

**Name this major VEIN that drains blood from the head and neck**



a. Carotid

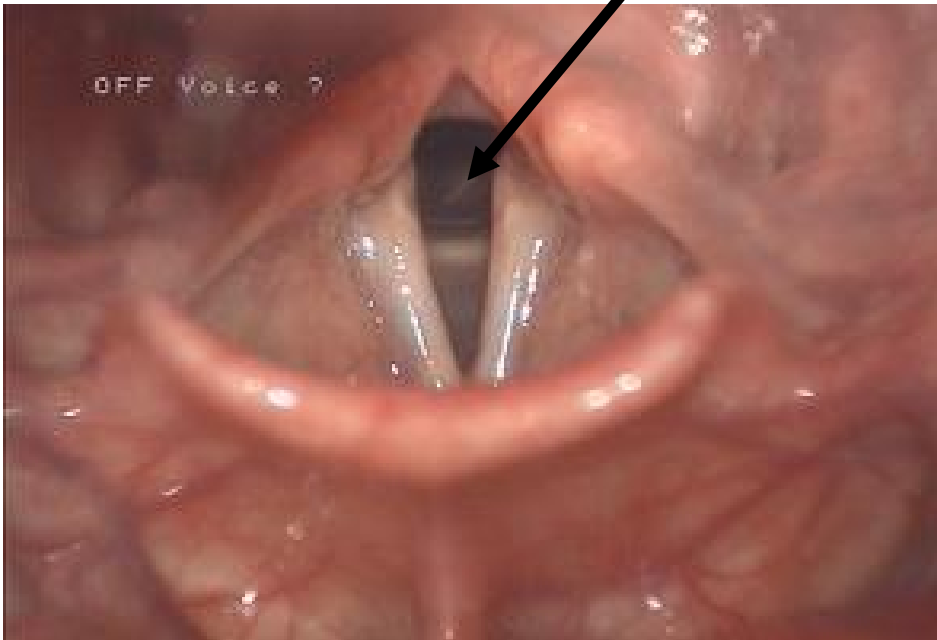
**b. Jugular**

c. Cephalic

d. Axillary

e. Subclavian

## 12. Which part of the voice box is indicated?



- a. Vocal cord
- b. False vocal cord
- c. Glottis
- d. Epiglottis
- e. pharynx